

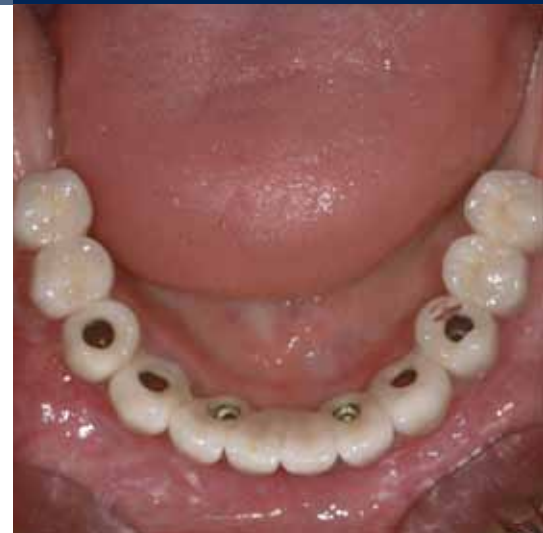# IMMEDIATE LOADING IN THE EDENTULOUS MANDIBLE

## SURGICAL, PROSTHETIC AND LABORATORY PROCEDURES WITH SCREW-RETAINED PROSTHETICS

a perfect fit™



Dr. Jan Spieckermann, Dr. Ulrich Glase  
Chemnitz, Germany



**Dr. med. dent. Jan Spieckermann – Prosthetics** After studying dentistry in Vienna and Greifswald and subsequent graduation, Dr. Spieckermann worked as a scientific employee in the Department of Prosthodontics, Medical Faculty, Dresden University of Technology. After two years of working in the Swedish public health service, he then trained to be a Dental Surgeon for Oral Surgery in the dental practice of Dr. Glase-Dr. Berger in Chemnitz. Dr. Spieckermann is a qualified and trained specialist for prosthetics of the German Society of Prosthodontics.

**Dr. med. Ulrich Glase – Surgery** After studying dentistry in Plovdiv/Bulgaria, studying medicine and gaining a doctorate in Jena, Dr. Glase completed his training as a specialist for OMF surgery at the Clinic for Oral, Maxillofacial and Plastic Surgery of the Friedrich Schiller University, Jena. After working as a senior physician in the Oral and Maxillofacial Surgery Department of the Chemnitz BKH, he opened his own practice in 1991, since then he has developed a special profile in the field of implant dentistry. Dr. Glase works as a consultant in implant dentistry.

### IMPLANTS USED

Tooth	18	17	16	15	14	13	12	11	21	22	23	24	25	26	27	28
Implant type																
Implant length																
Implant Ø																
Implant surface																

Tooth	48	47	46	45	44	43	42	41	31	32	33	34	35	36	37	38
Implant type					SL	SL	SL			SL	SL	SL				
Implant length					13.0	13.0	13.0			16.0	13.0	13.0				
Implant Ø					4.3	4.3	3.8			3.8	4.3	4.3				
Implant surface					P	P	P			P	P	P				

Implant type: ROOT LINE (RL)/SCREW-LINE (SL) Implant surface: Promote® (P)/Promote® Plus (PP)

### PROSTHETICS

- standard
  - platform switching
  - removable
  - fixed
  - crown
  - bridge
  - cemented
  - screw-retained
  - partially edentulous
  - edentulous
  - others
- 
- Universal Abutment
  - Esthomic® Abutment
  - Telescope Abutment
  - Gold-plastic Abutment
  - Ceramic Abutment
  - Custom Zirconia on Titanium Base
  - PEEK Abutment
  - Logfit® Abutment
  - Locator® Abutment
  - Ball Abutment
  - Bar Abutment
  - Vario SR Abutment
  - others

## INFORMATION ON PATIENT AND TREATMENT

Based on a clinical case at our dental practice, this case history describes the surgical, prosthetic and laboratory procedures for immediate implant placement with immediate loading in an edentulous mandible.

The 62-year-old patient presented for a consultation at our dental practice. She reported a history of recurrent loosening of the circular metal-ceramic bridge in the mandible.

The initial x-ray diagnosis revealed moderate atrophy of the mandible, the other teeth in her mandible exhibited horizontal and vertical bone cavities. After removing the bridge, the remaining teeth 34, 33, 32, 43, 44 showed

periodontal insufficiencies or caries damages. Following comprehensive diagnostics, an overall treatment concept including the maxilla was proposed to the patient. However, only the mandibular restoration was realized.

In the known protocols, the placement of 4 to 6 implants between the mental foramina in the anterior mandible is recommended. In the presented case, six CAMLOG® SCREW-LINE Implants were used. The implants must have a favourable primary stability when inserted. After implant placement, a long-term, immediately loaded, screw-retained provisional restoration was integrated. After a 3-month period of osseointegration and soft tissue healing, the definitive fixed prosthesis was fabricated.

### Initial findings

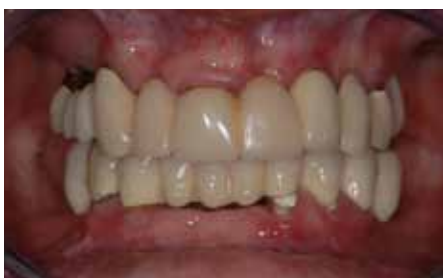

Fig. 1: Initial situation with recurrent loosening of the circular metal-ceramic bridge in the mandible.

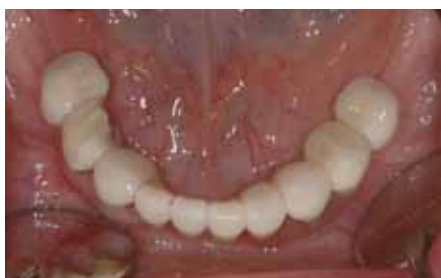

Fig. 2: Insufficient bridge in the mandible.

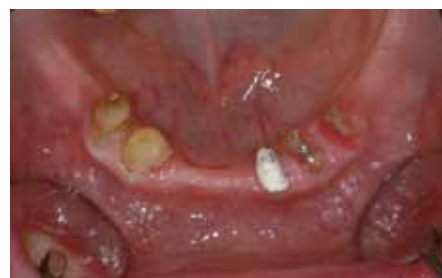

Fig. 3: State after removal of the bridge. Caries-destroyed residual teeth in the mandible, not worth being preserved.

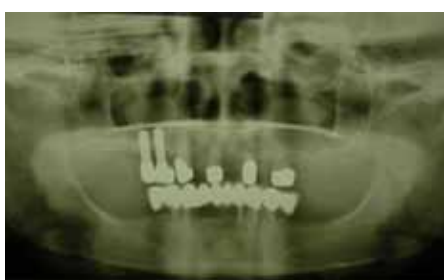

Fig. 4: OPG initial findings; moderate atrophy of the mandible, the remaining teeth in the mandible exhibit horizontal and vertical bone cavities.

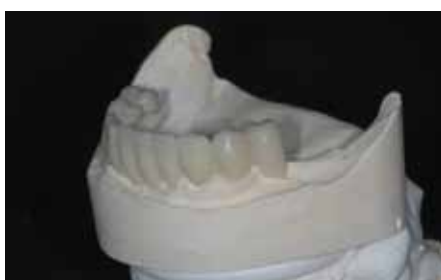

Fig. 5: A wax-up was made preoperatively and transferred to a temporary dish.

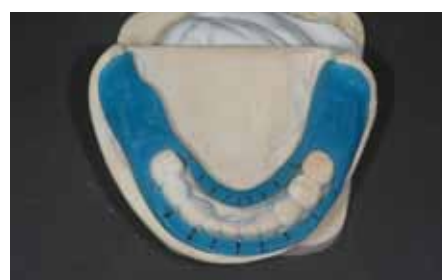

Fig. 6: Markings were made on a prepared open impression tray for use as a drilling orientation template.

### Implant placement

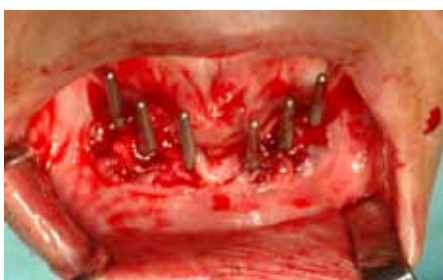

Fig. 7: Six CAMLOG® SCREW-LINE Promote® implants were placed interforaminally. Check on implant position using parallelizing abutments. Cylindrical gingiva formers were integrated intraoperatively, then the wound was sealed.

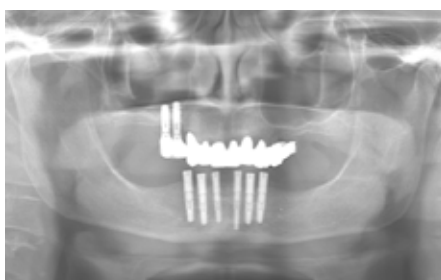


Fig. 8: The postoperative x-ray check shows the proper position of the implants.

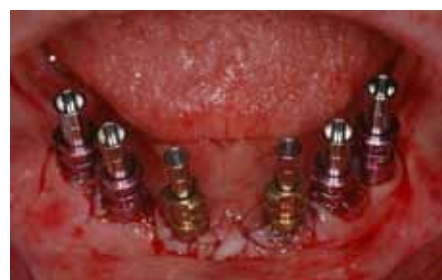

Fig. 9: Postoperatively inserted open-tray impression posts.

### Impression

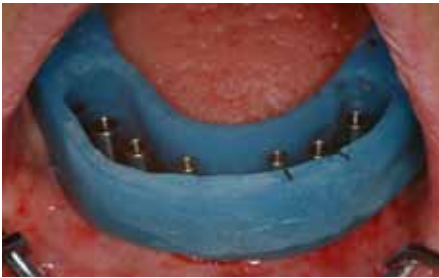

Fig. 10: Checking the open impression tray.

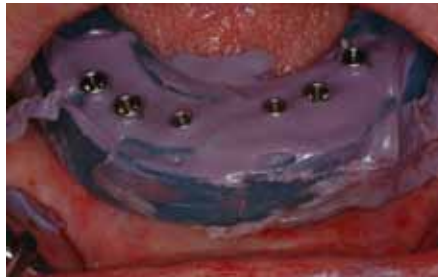

Fig. 11: Open impression using polyether – (Impregum®). The prosthetic interim restoration was performed directly postoperatively.

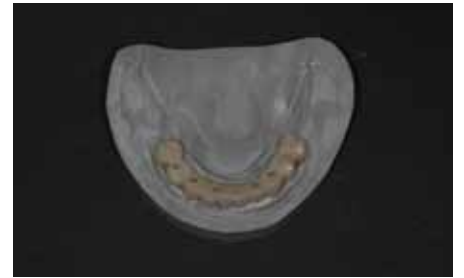


Fig. 12: Long-term temporary denture on PEEK abutments – model situation.

### Prosthetic treatment – temporary prosthesis

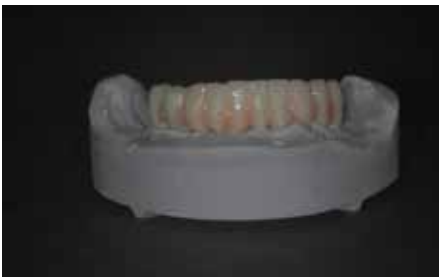

Fig. 13: During preparation of the long-term temporary bridge 35–45, the tooth positions were taken from a wax-up which had been created in advance.

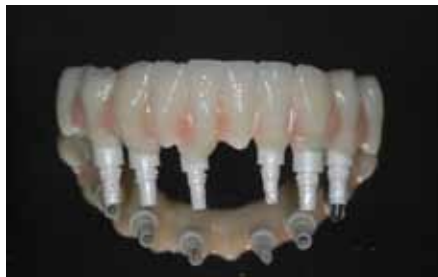

Fig. 14: Long-term temporary denture on PEEK abutments. A key aspect is the restoration's accuracy of fit which was checked clinically using the Sheffield test during insertion.

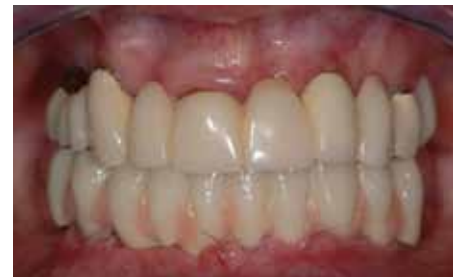

Fig. 15: Long-term temporary denture 1 week postoperatively. Status before suture removal, moderate soft tissue edema.

### Prosthetic treatment – definitive prosthesis

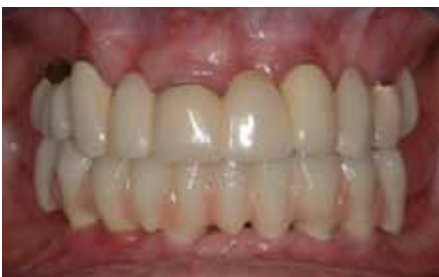

Fig. 16: Long-term temporary denture 16 weeks postoperatively.

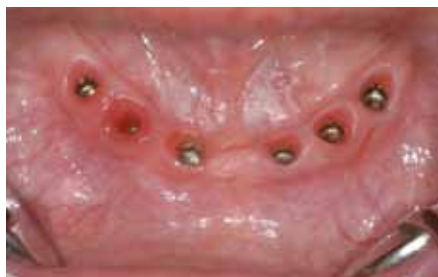

Fig. 17: Soft tissue situation after removing the long-term temporary denture at 16 weeks postoperatively. A mucositis was detected in region 43 and treated locally. Otherwise, stable soft tissue conditions.

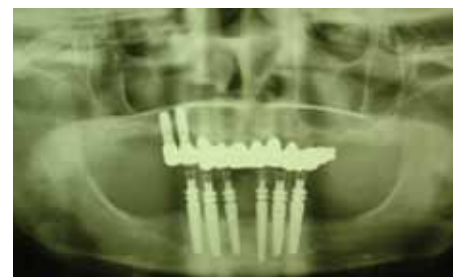

Fig. 18: Due to the firm peri-implant soft tissue, a control OPG was taken after inserting the impression posts for open tray impression.

### Dental laboratory

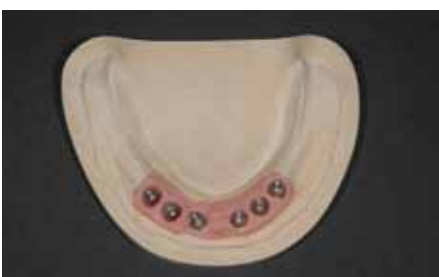

Fig. 19: CAMLOG® Vario SR straight abutments on the model.

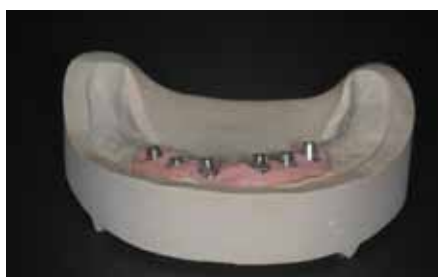

Fig. 20: CAMLOG® Vario SR straight abutments on the model.



Fig. 21: Scaffold modeling.



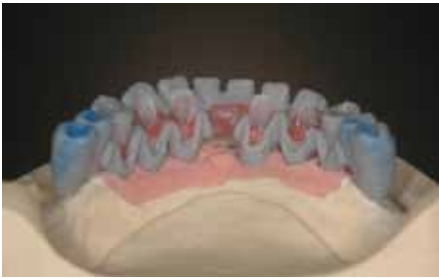

Fig. 22: Scaffold modeling.

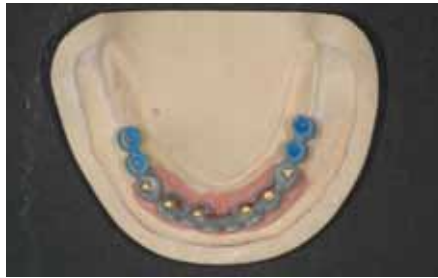

Fig. 23: Scaffold modeling.

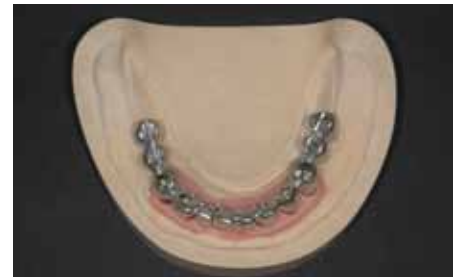

Fig. 24: Scaffold after casting and elaboration.

The scaffold was modeled with burn-out plastic copings, modeling plastic and wax. To avoid tensions in the modeling, separations and new joining together were made using pattern resin. A special embedding procedure enabled casting to be tension-free. The scaffold was checked on the model and in the mouth using the Sheffield test.

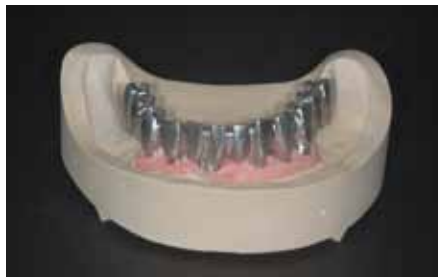

Fig. 25: Scaffold.

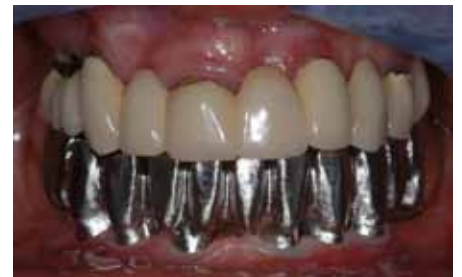

Fig. 26: The scaffold was checked in the mouth using the Sheffield test.

### Integration of definitive fixed prosthesis

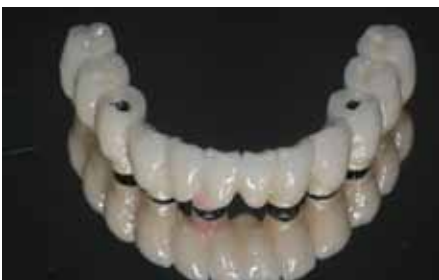

Fig. 27: Final screw-retained prosthesis after ceramic veneering.

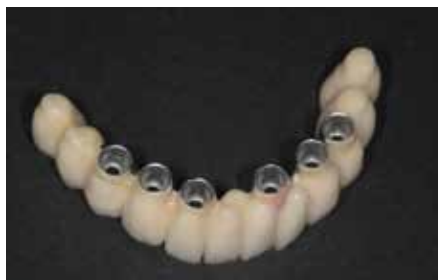

Fig. 28: Basal view of the final screw-retained prosthesis after ceramic veneering.

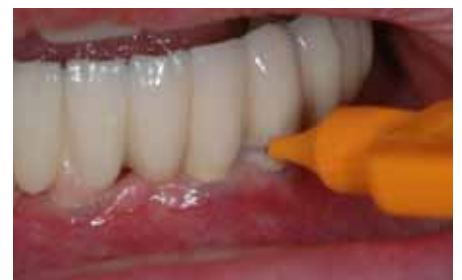

Fig. 29: After veneering, the restoration was tried in, checked for the ability to maintain hygiene and integrated definitively.

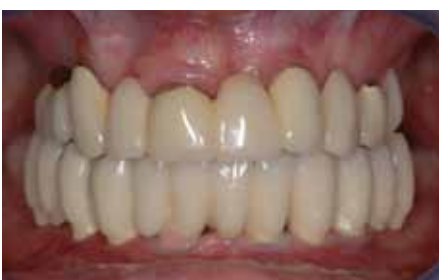

Fig. 30: Intraoral diagnosis after integrating the final restoration.

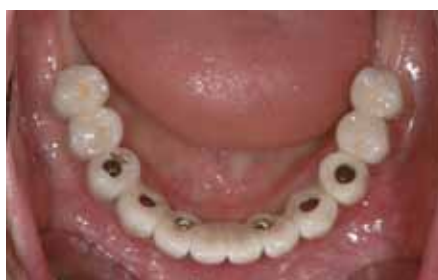

Fig. 31: Final restoration before closing the screw channels.

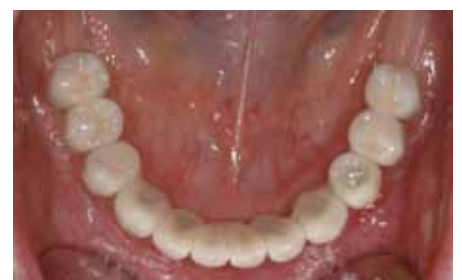

Fig. 32: Final restoration after closing the screw channels.

## CONCLUSIONS

Immediate implant placement with immediate loading of implants constitutes a type of restoration much requested by patients due to the fast esthetic and functional rehabilitation. But besides the benefits for dentists such as conserving bones and soft tissues, it also harbors great risks. A strict indication with intraoperative therapy decision is a basic pre-condition for a successful outcome. The long-term temporary restoration should be integrated promptly, if possible preferably on the day of implant placement, and should aim at reducing mechanical, infectious and chemical factors in the area of the gingiva.

Immediate implant placement with immediate loading is a routine restoration in our dental practice but only performed according to a very strict indication

with intraoperative therapy decision. We always hold a detailed preoperative risk consultation and propose implantological alternatives. Taking into account the strict indication and further preconditions for immediate implant placement, in selected clinical situations, functional high-quality treatment results are possible in the edentulous mandible. The presented screw-retained, long-term temporary restoration procedure constitutes a simple cost-effective option for rapid prosthetic restoration in the mandible. Besides the short duration of treatment and few visits to the dentist, the benefits for the patient are both the immediate esthetic functional rehabilitation and the avoidance of removable dentures and their associated disadvantages during the healing phase. We generally note high acceptance on the part of our patients.

### Initial situation

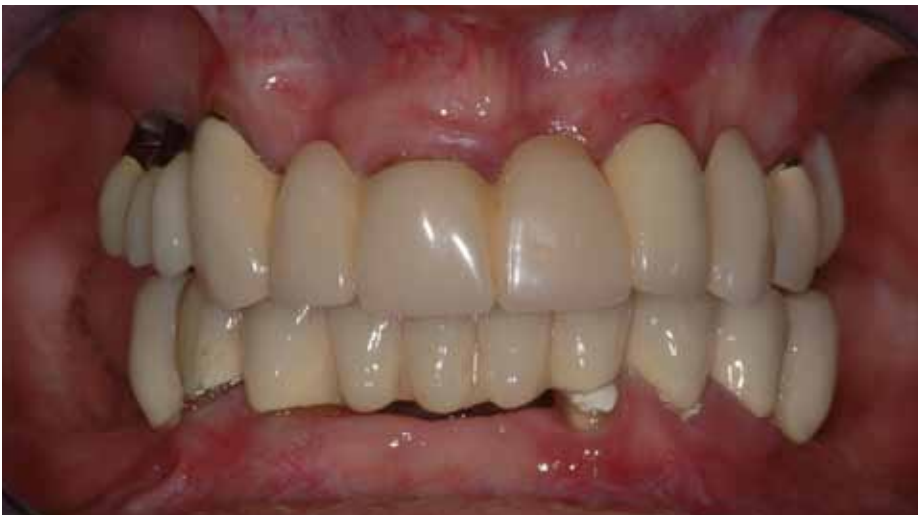

Fig. 33: Initial diagnosis.

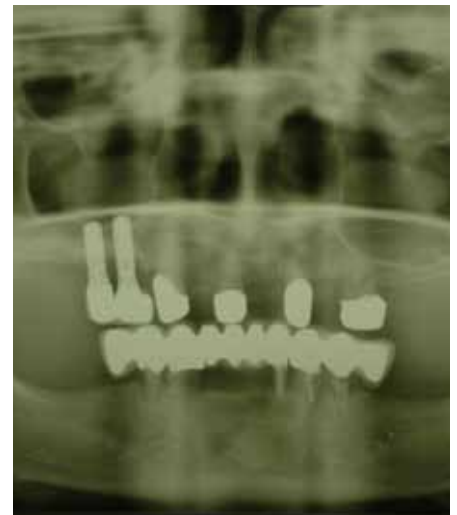

Fig. 34: OPG initial diagnosis.

### Final restoration

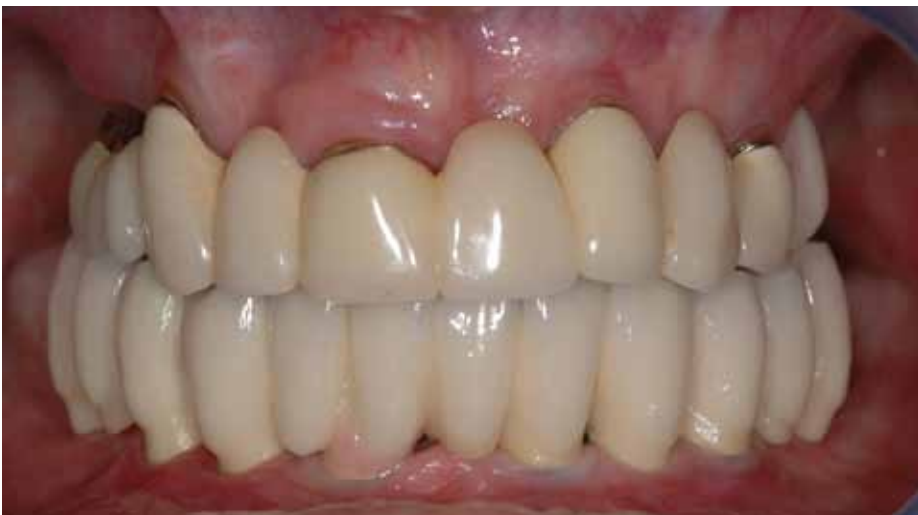

Fig. 35: Intraoral diagnosis after integrating the final restoration.

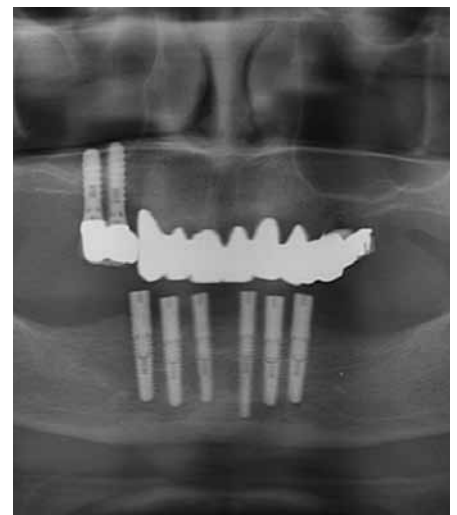

Fig. 36: OPG after implantation in the mandible.



## LITERATURE REFERENCES

### BECKER W, BECKER BE, HUFFSTETLERT S

Early functional loading at 5 days for Brånemark implants placed into edentulous mandibles: a prospective, open-ended, longitudinal study. *J Periodontol.* **2003** May; 74(5): 695-702.

### BRANEMARK PI, SVENSSON B, VAN STEENBERGHE D

Ten-year survival rates of fixed prostheses on four or six implants ad modum Branemark in full edentulism. *Clin Oral Implants Res* **1995**; 6(4): 227-31.

### DIERENS M, COLLAERT B, DESCHEPPER E, BROWAEYS H, KLINGE B, DE BRUYN H

Patient-centered outcome of immediately loaded implants in the rehabilitation of fully edentulous jaws. *Clin Oral Implants Res.* **2009** Oct; 20(10): 1070-7. Epub 2009 Aug 30.

### ESPOSITO M, GRUSOVIN MG, WILLINGS M, COULTHARD P, WORTHINGTON HV

Interventions for replacing missing teeth: different times for loading dental implants. *Cochrane Database Syst Rev.* **2009** Jan 21; (1): CD003878.

### JEMT T, BOOK K

Prosthesis misfit and marginal bone loss in edentulous implant patients. *Int J Oral Maxillofac Implants* **1996**; 11(5): 620-5.

### LI W, CHOW J, HUI E, LEE PK, CHOW R

Retrospective study on immediate functional loading of edentulous maxillas and mandibles with 690 implants, up to 71 months of follow-up. *J Oral Maxillofac Surg.* **2009** Dec; 67(12): 2653-62.

### ORTORP A, LINDEN B, JEMT T

Clinical experiences with laser-welded titanium frameworks supported by implants in the edentulous mandible: a 5-year follow-up study. *Int J Prosthodont.* **1999** Jan-Feb; 12(1): 65-72.

## CONTACT

Dr. Jan Spieckermann

Dr. Ulrich Glase

Practice of Dr. med. U. Glase - Dr. med. U. Berger

Doctors for Oral and Maxillofacial Surgery

Plastic Surgery

Particular focus of work: implant dentistry

Katharinenstr. 3a

09119 Chemnitz

Tel. +49 371 31 33 43, Fax +49 371 31 33 44

e-mail: [dr.spieckermann@mkg-glase-berger.de](mailto:dr.spieckermann@mkg-glase-berger.de)

[www.mkg-glase-berger.de](http://www.mkg-glase-berger.de)

## DENTISTRY

Anja Seifert

C1 Dentaltechnik GmbH

Augustusbürger Straße 228

09119 Chemnitz

Tel. +49 371 72 40 80, Fax +49 371 72 40 74

[www.c1dental.de](http://www.c1dental.de)

**HEADQUARTERS**

CAMLOG Biotechnologies AG | Margarethenstrasse 38 | CH-4053 Basel | Switzerland  
Tel +41 61 565 41 00 | Fax +41 61 565 41 01 | [info@camlog.com](mailto:info@camlog.com) | [www.camlog.com](http://www.camlog.com)

**camlog**